

# Mastocytosis: 2016 updated WHO classification and novel emerging treatment concepts

Peter Valent,<sup>1</sup> Cem Akin,<sup>2</sup> and Dean D. Metcalfe<sup>3</sup>

<sup>1</sup>Division of Hematology & Hemostaseology and Ludwig Boltzmann Cluster Oncology, Department of Medicine I, Medical University of Vienna, Vienna, Austria; <sup>2</sup>Division of Allergy and Immunology, Department of Medicine, Brigham and Women's Hospital, Harvard Medical School, Boston, MA; and <sup>3</sup>Mast Cell Biology Section, Laboratory of Allergic Diseases, National Institute of Allergy and Infectious Diseases, National Institutes of Health, Bethesda, MD

Over the past few years, substantial advances have been made in understanding the pathogenesis, evolution, and complexity of mast cell neoplasms. New diagnostic and prognostic parameters and novel therapeutic targets with demonstrable clinical impact have been identified. Several of these new markers, molecular targets, and therapeutic approaches have been validated and translated into clinical practice. At the same time, the classification

of mastocytosis and related diagnostic criteria have been refined and updated by the consensus group and the World Health Organization (WHO). As a result, more specific therapies tailored toward prognostic subgroups of patients have been developed. Emerging treatment concepts use drugs directed against KIT and other relevant targets in neoplastic mast cells and will hopefully receive recognition by health authorities in the

near future. This article provides an overview of recent developments in the field, with emphasis on the updated WHO classification, refined criteria, additional prognostic parameters, and novel therapeutic approaches. Based on these emerging concepts, the prognosis, quality of life, and survival of patients with advanced mastocytosis are expected to improve in the coming years. (*Blood*. 2017;129(11):1420-1427)

## Introduction

Mastocytosis comprises a heterogeneous group of disorders characterized by expansion and accumulation of neoplastic mast cells (MCs) in 1 or more organ systems.<sup>1-4</sup> In patients with systemic mastocytosis (SM), neoplastic MCs form focal and/or diffuse infiltrates in various internal organs, including the bone marrow (BM), spleen, liver, and gastrointestinal tract.<sup>1-4</sup> Regardless of the type of SM, the BM is involved in virtually all patients.<sup>4,5</sup> Skin involvement is usually found in patients with indolent SM (ISM), is less frequently detected in aggressive SM (ASM), and is rarely seen in MC leukemia (MCL).<sup>1,2</sup> Based on previous classification proposals and the classification of the World Health Organization (WHO), mastocytosis can be divided into subvariants of cutaneous mastocytosis (CM), in which no systemic involvement is found, systemic variants (SM), and localized MC tumors.<sup>1,6-11</sup>

Historically, mastocytosis was first described as a skin disease by Nettleship and Tay in 1869.<sup>12</sup> Seventy years later, in 1949, the first case of SM was reported<sup>13</sup> and over the next decades, different subvariants of CM and SM, reflecting different clinical presentations and outcomes, were described. Whereas the prognosis in CM is favorable,<sup>14</sup> the prognosis in patients with SM is variable, ranging from indolent with normal life expectancy to rapidly deteriorating courses.<sup>1,3,7-11,15-17</sup> Based on these observations, patients with SM were placed into distinct prognostic subgroups that in turn provided the basis of the first proposals to classify the disease.<sup>1,2,6,7</sup> Between 1991 and 2000, several additional useful clinical and laboratory parameters with obvious diagnostic and/or prognostic impact were identified and used to develop subgroup-specific criteria.<sup>18-25</sup> These criteria formed the basis of the first WHO classification, which was published in 2001.<sup>8,9</sup> The basic concept of this classification and the related criteria remain valid. However, over the ensuing years, additional, disease-specific variables were identified.<sup>10,11</sup> In addition, new prognostic parameters and more

effective therapies have been established. Based on these developments, the WHO classification of mastocytosis has recently been refined and updated.<sup>26,27</sup>

In the present article, we provide an overview of new developments in the field of mastocytosis, with focus on the updated WHO classification 2016, refinements in criteria and terminologies, major therapeutic targets, and novel treatment concepts.

## Updated WHO classification 2016

The basic concept of the previous WHO classification and the related split into CM, SM, and localized MC tumors<sup>8-10</sup> remains valid and has also been implemented in the updated version of the WHO classification in 2016.<sup>26,27</sup> The cutaneous form of the disease (CM) is divided into maculopapular CM, also termed urticaria pigmentosa, diffuse cutaneous mastocytosis, and localized mastocytoma of skin (see supplemental Table 1, available on the *Blood* Web site).<sup>8-10,27</sup> CM is usually diagnosed in childhood and has a good prognosis.<sup>14,28</sup> In many cases, the skin lesions fade away and disappear during puberty. Criteria to define cutaneous involvement in CM and to separate this disease from other cutaneous disorders and from SM have been published by an EU-US consensus group (supplemental Table 2).<sup>11,28</sup>

In contrast to CM, SM usually develops in adults. The pathognomonic feature in SM is the multifocal infiltration of MCs in various internal organs, including the BM.<sup>1-5</sup> The criteria to diagnose SM are depicted in Table 1. The major SM criterion is the multifocal clustering of MCs (at least 15 MCs/cluster) in 1 or more visceral organs (usually documented in the BM).<sup>8-10,27</sup> Minor SM criteria include an abnormal morphology of MCs (immature forms, spindling,

Submitted 1 September 2016; accepted 17 December 2016. Prepublished online as *Blood* First Edition paper, 28 December 2016; DOI 10.1182/blood-2016-09-731893.

The online version of this article contains a data supplement.

**Table 1. SM criteria**

|  |   |
|--|---|
| Major SM criterion   | Multifocal dense infiltrates of MCs ( $\geq 15$ MCs in aggregates) in BM biopsies and/or in sections of other extracutaneous organ(s)                     |
| Minor SM criteria  | a. $>25\%$ of all MCs are atypical cells (type I or type II) on BM smears or are spindle-shaped in MC infiltrates detected on sections of visceral organs |
|  | b. <i>KIT</i> point mutation at codon 816 in the BM or another extracutaneous organ   |
|  | c. MCs in BM or blood or another extracutaneous organ exhibit CD2 and/or CD25   |
|  | d. Baseline serum tryptase level $>20$ ng/mL (in case of an unrelated myeloid neoplasm, item d is not valid as an SM criterion)                           |
| If at least 1 major and 1 minor or 3 minor SM criteria are fulfilled, the diagnosis of SM can be established |   |

SM criteria were defined by the WHO in 2001 and have been confirmed in the WHO updates of 2008 and 2016.

decentralized oval nuclei or bi- or poly-lobed nuclei, hypogranulated cytoplasm), expression of CD2 and/or CD25 in MCs, an activating mutation at codon 816 of *KIT* (most frequently *KIT* D816V) in extracutaneous tissues, and a persistent serum tryptase concentration of  $>20$  ng/mL (Table 1).<sup>8-10</sup> When the major and at least 1 minor SM criterion or 3 minor SM criteria are detected, the diagnosis SM is established.<sup>8-10</sup>

In the updated WHO classification, SM is divided into ISM, smoldering SM (SSM), SM with an associated hematologic (non-MC lineage) neoplasm (SM-AHN), ASM, and MCL (Table 2).<sup>26,27</sup>

SSM is a new SM category in the WHO classification. In the initial WHO proposal of 2001, SSM was mentioned as a provisional subvariant of ISM.<sup>8-10</sup> Later, in 2007, our EU-US consensus group proposed SSM as a separate SM category.<sup>11</sup> The prognosis of patients with SSM is less favorable compared with ISM but favorable compared with ASM or MCL. Another provisional subentity of SM is BM mastocytosis, a subvariant characterized by absence of skin lesions, low burden of MCs, and a good prognosis.<sup>8,11</sup> Although relevant clinically, this type remains a provisional type of SM in the updated WHO classification.<sup>27</sup>

AHN is a novel abbreviation and can be used instead of (or synonymously to) the previous term “associated hematologic non-mast cell-lineage disease.”<sup>26,27</sup> Diagnostic criteria to define SSM (B-findings) and ASM (C-findings) remain unchanged in the updated WHO classification 2016.<sup>27</sup> These criteria are depicted in supplemental Table 3.

Additional refinements have also been implemented in the updated WHO classification of mastocytosis.<sup>27</sup> Thus, because of its exceptional rarity, extracutaneous mastocytoma has been removed from the updated classification. ASM is now divided into an untransformed variant and a variant “in transformation to MCL” (ASM-t). This delineation was proposed by the EU-US consensus group in 2014.<sup>29</sup> In patients with ASM-t, the percentage of MCs in BM smears is  $\geq 5\%$  but less than 20%.<sup>29</sup> When the percentage of MCs in the BM smear reaches 20%, the diagnosis changes from ASM-t to MCL per definition. Of note, the primary criterion of MCL remains a percentage count of MCs in BM smears of at least 20% in the updated WHO classification.<sup>27</sup> Traditionally, MCL is split into a (less frequent) classical variant in which MCs compose at least 10% of all circulating white blood cells, and an aleukemic MCL variant in which MCs in peripheral blood smears are less than 10%.<sup>8-10</sup> This delineation also applies in the updated WHO classification.<sup>27</sup> More recently, MCL has been divided into a chronic form without obvious organ damage (no C-findings

present) and a more aggressive (acute) variant, termed acute MCL where organ damage (C-findings) is present (supplemental Table 4).<sup>29</sup> The delineation into acute and chronic MCL is also mentioned in the updated WHO classification.<sup>27</sup> Finally, MCL can be split into primary variants and secondary variants (supplemental Table 4). Notably, patients with ASM-t and MC sarcoma frequently progress into (acute) MCL.

Several earlier as well as more recent studies have confirmed the prognostic value of the WHO classification relating to progression-free and overall survival.<sup>30-33</sup> Notably, patients with ISM have an excellent prognosis with normal or near-normal life expectancy, whereas the prognosis and survival are less favorable in advanced SM. In all studies published to date, the prognosis of MCL is quite unfavorable.<sup>30-34</sup> In most MCL patients, primary drug resistance is found and the median survival time is  $<1$  year. Patients with chronic MCL are very rare and may have a slightly better prognosis.<sup>29,35</sup> However, overall, the outcome of patients with MCL is poor regardless of the disease subtype. A variant with a similarly poor outcome is MC sarcoma, a rare local tumor that consists of immature MCs and shows a sarcoma-like growth in local tissue sites. As mentioned, MCS usually transforms to MCL within a short time.

## Therapeutic targets identified in neoplastic MCs in advanced SM

Several different therapeutic targets have been identified in neoplastic MCs and their disease-initiating stem and progenitor cells in recent years. Several of these target antigens, such as mutated *KIT* variants, have been the focus of clinical trials with quite encouraging results. Other targets have been identified very recently and are currently being validated in preclinical studies or in ongoing clinical trials. In the following section, the most important therapeutic targets are discussed.

### *KIT* and oncogenic mutant forms of *KIT*

The oncogenic *KIT* mutation D816V is detectable in  $>80\%$  of all patients with SM and in  $>90\%$  of all cases with typical ISM.<sup>18-20,36</sup> *KIT* D816V is considered a relatively weak driver that promotes MC differentiation and maturation rather than MC proliferation.<sup>37,38</sup> Correspondingly, MCs in ISM are nonproliferating cells and progression to ASM is rare.<sup>7-10,30</sup> In addition, *KIT* D816V is rarely detected in patients without overt SM: when these patients are also suffering from an MC activation syndrome (MCAS), the final diagnosis is primary (clonal) MCAS.<sup>11</sup> When no MCAS criteria are met, the published proposal is to call the condition monoclonal MCs of uncertain significance.<sup>11</sup> Whereas patients with monoclonal MCs of uncertain significance are followed without specific therapy using serum tryptase levels as primary disease-related parameter, patients with MCAS are treated by anti-mediator-type drugs.

In patients with established SM, *KIT* D816V may serve as a “co-driver” of cell survival and proliferation in neoplastic MCs and their progenitors in ASM and MCL<sup>36</sup>; therefore, *KIT* D816V is considered a major therapeutic target in advanced SM, and several drugs targeting the mutant have been developed in preclinical studies. However, *KIT* D816V confers resistance against imatinib, masitinib, and several other *KIT*-targeting drugs.<sup>39,40</sup> A number of other oncogenic variants of *KIT* have also been identified in patients with SM, especially in childhood CM, but also in MCL.<sup>41-43</sup> Although several of these mutations (such as that in codon 816) also mediate imatinib resistance, other mutant forms, such as K509I or F522C, are sensitive to imatinib (Table 3).<sup>44,45</sup>

**Table 2. WHO classification of mastocytosis 2016**

|   |
|---|
| <b>CM</b>                                   |
| MPCM = UP                                   |
| <b>DCM</b>                                  |
| Mastocytoma of skin (cutaneous mastocytoma) |
| <b>SM</b>                                   |
| ISM   |
| SSM   |
| SM with AHN*                                |
| ASM   |
| MCL†  |
| MC sarcoma                                  |

DCM, diffuse CM; MPCM, maculopapular CM.

\*The previous term SM with clonal hematologic non–mast cell-lineage disease and the new abbreviation AHN can be used synonymously.

†Subvariants of MCL are shown in supplemental Table 4.

Moreover, in a small subset of patients with advanced SM, neoplastic MCs express wild-type (WT) *KIT*. These patients may also respond to imatinib unless other oncogenic mechanisms introduce resistance.<sup>44</sup>

### KIT-downstream signal transduction molecules

A number of downstream signal transduction molecules and pathways are involved in KIT-dependent oncogenesis. These potential target molecules include, among others, the phosphatidylinositol 3 kinase,<sup>46,47</sup> the mechanistic (formerly mammalian) target of rapamycin,<sup>48</sup> STAT5,<sup>49</sup> and the tyrosine-protein kinase FES.<sup>50,51</sup> Several of these targets are clinically relevant, and targeted drugs directed against these molecules have been developed. However, the exact value of these targets in advanced SM remains at present unknown because no larger studies have been conducted and first clinical pilot studies have not shown disease-modifying effects.<sup>52</sup>

### KIT-independent oncogenic drivers and pathways

Because *KIT* D816V per se may not be able to transform a stem cell clone into a full-blown malignancy,<sup>37,38</sup> recent efforts have focused on additional, KIT-independent targets and target pathways. Indeed, in advanced SM and especially in patients with SM-AHN, several additional drivers, mutations, and signaling pathways have been identified.<sup>53–57</sup> Sometimes, these pathways are also or even exclusively expressed in the AHN portion of the disease. Other signal cascades are believed to cooperate with KIT D816V and/or D816V KIT-downstream molecules to trigger oncogenic growth of neoplastic MCs. Somatic gene defects frequently detected in advanced SM and SM-AHN include mutations in *TET2*, *SRSF2*, *ASXL1*, *CBL*, *RUNX1*, *NRAS*, and *KRAS*.<sup>53–56</sup> In addition, the *JAK2* mutation V617F has been described in patients with SM-AHN.<sup>58,59</sup> Other pro-oncogenic key mutants detected in unrelated (non-MC lineage) myeloid neoplasms, such as *CALR* mutations, *PDGFRA* and *PDGFRB* mutations, or *BCR/ABL1*, are usually not found in indolent or advanced SM, including SM-AHN.

### Epigenetic targets and survival-related molecules

So far, little is known about epigenetic factors and events involved in the evolution and/or progression of SM. Previous studies have shown that hypermethylation of *FAS* and other tumor suppressor molecules play a potential role in oncogenesis in MCL.<sup>60</sup> It has also been reported that neoplastic MCs in SM express the BET bromodomain molecule BRD4, a well-known regulator of MYC.<sup>61</sup> Therefore, BRD4 has recently been discussed as a potential target of therapy in advanced SM. There are also several survival-related molecules

that may serve as potential targets of therapy. Among these are members of the BCL-2 family<sup>62</sup> and the heat shock proteins (HSPs), such as HSP32, also known as heme oxygenase 1 or HSP90.<sup>63,64</sup>

### Immunogenic cell-surface targets

During the past 15 years, several clinically relevant cell-surface targets have been identified on neoplastic BM cells, and effective antibody-based drugs acting through these antigens have been developed. Several of these target antigens are also expressed on neoplastic MCs in advanced SM (Figure 1). These molecules include, among others, the brentuximab-target CD30, the gemtuzumab-ozogamicin target CD33, the alemtuzumab target CD52, and the interleukin-3 receptor  $\alpha$  chain CD123.<sup>65–71</sup> Antibody-based drugs directed against these targets may induce cell lysis or apoptosis in neoplastic MCs.<sup>66,69,70</sup> In addition, initial clinical observations suggest that antibody-based drugs exert antineoplastic effects in patients with advanced SM.<sup>72,73</sup> A summary of surface markers and potential targets expressed by neoplastic MCs is shown in Figure 1 and supplemental Table 5. Another emerging approach is to target cell-surface antigens involved in drug resistance. These antigens include, among others, the “don’t eat me” receptor IAP-1 (CD47), the multidrug resistance protein 1 (CD243), and the immunological checkpoint target PD-L1 (CD274). The latter antigen has recently been detected in neoplastic MCs in SM.<sup>74</sup> Whether these antigens play a role in drug resistance in advanced SM is under investigation.

### LSCs

The concept of leukemic stem cells (LSCs) predicts that antineoplastic treatment approaches are only curative when eliminating most or all disease-propagating cells (ie, LSCs). In fact, in contrast to more mature clonal cells, LSCs have self-renewing and thus unlimited disease-propagating capacity<sup>75,76</sup>; therefore, LSCs represent a key target in curative antileukemic treatment concepts. However, although MCs are considered to be derived from hematopoietic stem cells, little is known about LSCs in advanced SM and MCL. More recently, the phenotype of the NSG mouse-repopulating MCL LSCs has been established.<sup>77</sup> These LSCs reside within a very small CD34<sup>+</sup>/CD38<sup>–</sup> population of the malignant clone.<sup>77</sup> In addition, it has been reported that these cells display several cell-surface and cytoplasmic target antigens, including CD44, CD47, and KIT, and often also CD33, CD52, and CD123 (Figure 1).<sup>77</sup> Future studies will address the question as to whether and how MCL LSCs can be eliminated most efficiently, with the aim to establish a basis for development of curative therapies. An important issue in this regard is intrinsic (natural) stem cell resistance that is often associated with stem cell dormancy, but also with stem cell–niche interactions and expression of resistance-related antigens, such as PD-L1. Whereas cycling LSCs may be accessible to small molecule type inhibitors such as midostaurin, the (more frequent) dormant or slowly cycling LSCs may be less responsive or even resistant. To eradicate these cells antibody-based drugs may be required. Cell-surface antigens detectable on LSCs and MCs in patients with SM are shown in Figure 1. Whether antibody-based drugs directed against CD30, CD33, CD52, or CD123 are indeed able to eradicate MCL LSCs in vivo in NSG mice or even in patients with advanced SM (or MCL) is currently unknown.

## Therapeutic options for patients with advanced SM

At present, there is no generally accepted first-line standard therapy for patients with advanced SM. Until recently, these patients were treated

**Table 3. Available drugs, major drug targets, and effect profiles**

| Drug                 | Major drug targets   | Growth-inhibitory effects on neoplastic MCs expressing KIT D816V*  |
|----------------------|--|--|
| Imatinib             | KIT WT, KIT K509I, KIT F522C, KIT V560G, FIP1L1-PDGFR $\alpha$ /B                    | KIT D816V confers resistance to imatinib   |
| Masitinib            | KIT WT, LYN, PDGFR $\alpha$ /B   | KIT D816V confers resistance to masitinib  |
| Nilotinib            | KIT WT, KIT D816V, KIT F522C, KIT V560G, KIT K509I, PDGFR $\alpha$ /B                | KIT D816V confers partial resistance against nilotinib; however, some effects were seen in a pilot trial in SM patients  |
| Dasatinib            | KIT WT, KIT D816V, KIT F522C, KIT V560G, KIT K509I, PDGFR $\alpha$ /B, BTK, LYN      | Growth-inhibitory effects are seen in most in vitro cell systems; however, because of the short half-life of the drug in vivo, no major durable effects were seen in SM patients |
| Midostaurin (PKC412) | KIT WT, KIT 509I, KIT F522C, KIT V560G, KIT D816V, FES, FLT3, PDGFR $\alpha$ /B, SYK | Growth-inhibitory effects are seen in most cell systems and in most patients with advanced SM; in addition, midostaurin blocks IgE-dependent histamine release†                  |
| Cladribine (2CdA)    | Nucleoside metabolism  | Growth-inhibitory effects are seen in most cell systems and in a subset of patients with advanced SM   |
| IFN- $\alpha$        | Unknown‡   | Only transient and slight effects were seen in most patients with SM   |

PDGFR $\alpha$ /B, platelet-derived growth factor receptor  $\alpha$ /B.

\*The KIT D816V mutant is detected in a majority of patients with advanced SM. However, in a few patients with MCL or other rare forms of advanced SM, other targets are detectable and may respond to imatinib and masitinib.

†Midostaurin produces clinically meaningful (major) responses in about 60% of all patients with advanced SM, including a subset of patients with MCL.

‡IFN- $\alpha$  may exert growth-inhibitory effects on MC progenitor cells.

with more or less effective (palliative) antineoplastic drugs or interferon- $\alpha$  (IFN- $\alpha$ ).<sup>78-80</sup> Cladribine (2CdA), however, is a quite effective agent. This drug induces clinically meaningful responses in about 50% of all patients with advanced SM<sup>80-82</sup>; however, even when treated with cladribine or poly-chemotherapy (poly-CT), many patients develop resistance. Therefore, new treatment concepts have been developed and have been tested in clinical trials and clinical practice in

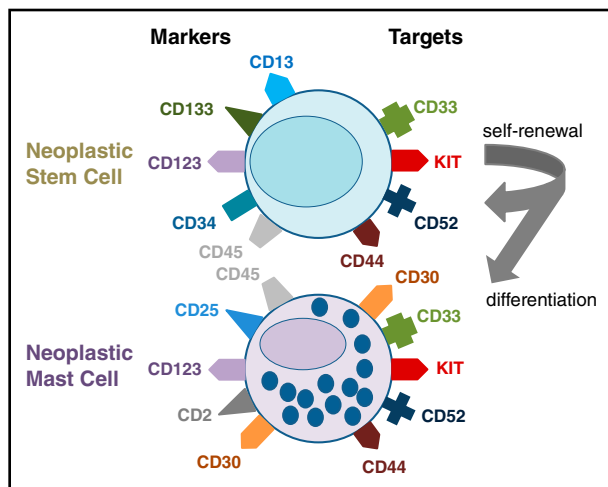
recent years. In the following paragraphs, 2 important new treatment approaches are discussed and a putative therapeutic standard algorithm for SM patients is presented.

## HSCT

Allogeneic hematopoietic stem cell transplantation (HSCT) appears to be an important approach to consider in patients with advanced SM, including MCL. The effect of this therapy has recently been summarized and discussed based on available data.<sup>83</sup> HSCT should be considered for those who are young and fit and have a suitable transplant donor. The outcome of transplanted patients (overall survival and progression-free survival) appears to be favorable in non-transformed patients with ASM and SM-AHN compared with those who have overt MCL.<sup>83</sup> In addition, it has been reported that myeloablative conditioning is associated with a better outcome compared with results obtained with nonmyeloablative conditioning.<sup>83</sup> So far, it remains unknown whether and what debulking therapy is required before HSCT in these patients.<sup>83,84</sup> One reasonable approach may be to induce a clinically measurable response using cladribine or poly-CT before HSCT is performed. Following such a strategy may help define whether the disease is indeed responsive and whether the patient can tolerate intensive therapy. Another unresolved question is whether HSCT should be followed by maintenance therapy using specific agents, such as midostaurin. Finally, it remains an open question as to whether all patients with rapidly progressing ASM and MCL would benefit from HSCT.<sup>83,84</sup> In particular, the risk of transplant-related mortality in elderly patients (>60 years) is rather high, and the same holds true for patients suffering from certain comorbidities (eg, cardiovascular, metabolic). Therefore, in many patients, HSCT may not be an option.

## KIT tyrosine kinase inhibitors

The most promising KIT inhibitor developed to date for patients with advanced SM appears to be midostaurin.<sup>85-89</sup> This drug, formerly



**Figure 1. Markers and targets expressed on neoplastic stem cells and mast cells in patients with SM.** Neoplastic stem cells propagate the malignancy through their self-renewal capacity and ability to undergo asymmetrical cell division, resulting in daughter cells that are committed to differentiate into neoplastic mast cells (arrows). In common with normal stem cells, neoplastic stem cells in SM display CD34 and KIT as well as CD133. In addition, these cells usually express the cell-surface targets CD33, CD44, and CD52; however, they do not express CD2, CD25, or CD30. Some of the markers used to define stem cells or mast cells, such as KIT, also serve as molecular targets of therapy. Neoplastic mast cells themselves usually display CD2, CD25, and CD30 in an aberrant manner together with KIT, but lack CD34. In addition, neoplastic mast cells in SM express a number of potential therapeutic cell-surface targets, including CD30, CD33, CD52, or CD123.



**Table 4. Disease-modifying therapies in mastocytosis: current recommendations and emerging new treatment approaches**

| Diagnosis/disease variant                 | Recommended first-line therapy* | Emerging new treatment options (second- and third-line/future therapies) |
|---|---------------------------------|--|
| ISM                                       | No                              | —  |
| SSM                                       | No or cladribine†               | Midostaurin in select cases‡   |
| ISM-AHN                                   | AHN-therapy ± HSCT              | Midostaurin ± HSCT§  |
| ASM-AHN                                   | AHN-therapy ± HSCT              | AHN therapy + midostaurin + HSCT   |
| ASM slow                                  | IFN-α, cladribine               | Midostaurin ± HSCT   |
| ASM rapid                                 | Cladribine, poly-CT, HSCT       | Midostaurin + poly-CT + HSCT   |
| ASM-t                                     | Cladribine, poly-CT, HSCT       | Midostaurin + poly-CT + HSCT   |
| cMCL                                      | Cladribine, CT, poly-CT         | Midostaurin, CT + midostaurin ± HSCT                                     |
| aMCL                                      | Poly-CT + HSCT                  | Poly-CT + midostaurin + HSCT   |
| MCS                                       | Radiation + poly-CT             | Poly-CT + radiation + HSCT   |
| ASM/MCL with an imatinib-sensitive target | Imatinib                        | Masitinib, midostaurin   |

aMCL, acute MCL; cMCL, chronic MCL; MCS, mast cell sarcoma.

\*These recommendations are based on expert opinion and a few clinical trials published thus far, but are not based on larger controlled clinical trials, which is mainly because of the rarity of the disease.

†Cladribine is recommended for a small group of SSM patients suffering from severe (life-threatening) anaphylaxis in whom other treatments failed.

‡Midostaurin is currently not (yet) approved for treatment of SSM or advanced SM.

§Midostaurin may be considered in these patients when the AHN component of the disease expresses a clinically relevant drug target (KIT D816V or FLT3 ITD).

||Imatinib-sensitive targets detected in ASM/MCL include WT KIT, rare mutant forms of KIT, and PDGFRA/B mutants. These mutants are also sensitive against masitinib and midostaurin.

named PKC412, blocks the kinase activity of WT KIT but also the kinase activity of various mutant forms, including KIT D816V.<sup>86-88</sup> In addition, midostaurin counteracts immunoglobulin E (IgE)-dependent release of histamine in MCs and basophils.<sup>51,90</sup> First data from a phase 2 multicenter trial using midostaurin in advanced SM are encouraging and suggest that the drug induces clinically meaningful responses in most patients, with an overall response rate of 60% and major responses seen in 45% of all patients.<sup>91</sup> Although higher response rates were seen in ASM, patients with MCL also responded to midostaurin.<sup>91</sup> The responses seen in ASM and MCL were often durable and resulted in an improved survival compared with historic controls.<sup>92</sup> In particular, the median overall survival in the study group was 28.7 months and progression-free survival 14.1 months.<sup>91</sup> Finally, despite nausea and vomiting, midostaurin was found to improve the quality of life and mediator-related symptoms in these patients.<sup>91,93</sup> The drug has recently been submitted to health authorities and, once approved, will be considered front-line standard therapy in patients with (untreated or pretreated and resistant) advanced SM. In addition, midostaurin can be regarded standard therapy in drug-resistant patients with advanced SM, regardless of expression or lack of KIT D816V. However, it is important to recognize that midostaurin is unable to eradicate the disease in advanced SM and that relapses are seen quite frequently<sup>91,93</sup>; therefore, combination strategies have been proposed. For example, midostaurin may be useful in the context of HSCT, either for bridging patients who are in need of debulking or as maintenance therapy after HSCT. Another strategy may be to combine midostaurin with other antineoplastic agents that exert reasonable effects on neoplastic cells in advanced SM, such as cladribine. Indeed, strong synergistic antineoplastic effects were obtained when treating neoplastic KIT D816V<sup>+</sup> MCs in vitro with the drug combination midostaurin + cladribine.<sup>57,88</sup> Another option may be to combine midostaurin with chemotherapy or with targeted antibodies known to kill neoplastic stem cells in advanced SM.

Several other new KIT-targeting tyrosine kinase inhibitors capable of blocking the kinase activity of the D816V mutant are under development; however, these agents have not been tested in clinical studies to date. Other tyrosine kinase inhibitors are directed against WT KIT but are not capable (or are less capable) of inhibiting the kinase activity of KIT D816V. These drugs include imatinib, nilotinib, and masitinib. Data obtained in recent clinical

trials have shown that these drugs exert some beneficial effects on mediator-related symptoms and sometimes induce a decrease in (presumably normal) MCs in patients with SM.<sup>80,94-97</sup> However, major disease-modifying responses are largely restricted to those patients in whom neoplastic cells express a sensitive target receptor, such as WT KIT, a rare imatinib-sensitive and/or masitinib-sensitive KIT mutant (other than KIT D816V), or a sensitive PDGFRA or PDGFRB mutant.<sup>80,94-97</sup>

#### **Toward personalized medicine in SM: current treatment algorithms**

In patients with ISM and SSM, antineoplastic therapy is usually not required and should be avoided.<sup>2,11,15,98-100</sup> In some patients with (progressive) SSM, antineoplastic therapy may be indicated to decrease the risk of severe life-threatening anaphylaxis (comparable to cytoreduction in *JAK2*-mutated patients to minimize the risk of fatal thromboembolism). For these patients, cladribine should be considered because this drug has been described to reduce the MC burden and lowering the risk of severe mediator-related events in such patients.<sup>101</sup> Whether midostaurin exerts similar beneficial effects in SSM remains unknown. However, it is known that in SSM, MC proliferation is largely dependent on KIT D816V and MC activation is often triggered by IgE-dependent mechanisms; therefore, midostaurin may be an optimal targeted drug for treatment of SSM.

In nontransplantable patients with slowly progressing ASM or chronic MCL, midostaurin is a forthcoming standard of therapy.<sup>91-93</sup> For the moment, however, most patients receive initial treatment with cladribine. Major responses are obtained in a subset of these patients and responses are often durable.<sup>80-82</sup> If this is not the case or the patient presents with rapidly progressing ASM or acute MCL, more intensive therapy is usually required.<sup>11,80,100</sup> These patients are candidates for poly-CT and HSCT.<sup>83,84,100</sup> If HSCT cannot be performed, poly-CT alone, cladribine, or midostaurin may be considered. One reasonable approach would be to induce a good response with poly-CT or cladribine and to maintain the response with midostaurin. Similarly, midostaurin might be considered as maintenance after HSCT, especially when residual KIT D816V<sup>+</sup> disease is detectable. In drug-resistant cases, hydroxyurea is usually recommended as a palliative drug.<sup>11</sup> In all

patients, additional histamine receptor blockers should be applied and, depending on mediator-related symptoms, glucocorticosteroids may be required.<sup>2,11,98-100</sup> For those with osteopenia, osteoporosis, or osteolysis, bisphosphonate therapy has to be considered.<sup>11</sup> A special situation is SM-AHN. In these patients, the SM component should be managed as if no AHN was detected, and the AHN should be treated as if no SM was found, with recognition that in the SM context, any AHN counts as secondary.<sup>11,100</sup> For example, in a patient with ISM-AML, the AML component must be regarded as secondary (high-risk) AML, and the patient should be treated as having high-risk AML. A summary of current treatment options for patients with ISM, SSM, and advanced SM is shown in Table 4. Treatment response criteria for indolent and advanced SM are also available. For details concerning these criteria, we refer to the available literature.<sup>11,102,103</sup>

## Concluding remarks

During the past few years, novel insights into the pathogenesis of SM and its variants have accumulated. In addition, major advances in the diagnosis, prognostication, and therapy of these patients have been made. Today, SM is regarded as a stem cell–derived hematologic neoplasm that manifests in different forms, including indolent variants and advanced entities. Depending on the WHO category, SM exhibits a variable clinical course, ranging from asymptomatic with normal life expectancy to rapidly progressing with fatal outcome. Over the past few years, several novel targets have been identified in neoplastic MCs and several novel treatment concepts have been established using more or less specific targeted drugs. These drugs include, among others, cladribine, the multikinase blocker midostaurin, and the CD30-targeting antibody-conjugate brentuximab. First clinical trials have shown beneficial effects with midostaurin in advanced SM. However, many patients do relapse after having been treated with cladribine and/or midostaurin. In patients with

drug-resistant or rapidly progressing SM, poly-CT is still considered a standard of therapy. And for those who respond to initial therapy, HSCT is a reasonable option that should be considered in all eligible patients.

## Acknowledgments

This study was supported by the Austrian Science Fund (F4701-B20 and F4704-B20) (P.V.) and the Division of Intramural Research, National Institute of Allergy and Infectious Diseases, National Institutes of Health (D.D.M.).

## Authorship

**Contribution:** All authors contributed substantially to the content of the article by reviewing the literature and the published material, by discussing specific open questions, and by writing parts of the document. All authors approved the final manuscript version.

**Conflict-of-interest disclosure:** P.V. served as a consultant in a Novartis-sponsored global trial on midostaurin; received research grants from Novartis, Deciphera, and Blueprint; and honoraria from Novartis and Deciphera. C.A. received honoraria from Novartis, Deciphera, and Patara. D.M.M. no competing financial interests.

**ORCID profiles:** P.V., 0000-0003-0456-5095; C.A., 0000-0001-6301-4520; D.D.M., 0000-0002-7781-8260.

**Correspondence:** Peter Valent, Department of Internal Medicine I, Division of Hematology and Hemostaseology and Ludwig Boltzmann Cluster Oncology, Medical University of Vienna, Waehringer Guertel 18-20, A-1090 Vienna, Austria; e-mail: peter.valent@meduniwien.ac.at.

## References

- Parwaresch MR, Horny HP, Lennert K. Tissue mast cells in health and disease. *Pathol Res Pract*. 1985;179(4-5):439-461.
- Valent P, Akin C, Sperr WR, et al. Diagnosis and treatment of systemic mastocytosis: state of the art. *Br J Haematol*. 2003;122(5):695-717.
- Metcalfe DD. Mast cells and mastocytosis. *Blood*. 2008;112(4):946-956.
- Horny HP, Parwaresch MR, Lennert K. Bone marrow findings in systemic mastocytosis. *Hum Pathol*. 1985;16(8):808-814.
- Horny HP, Valent P. Diagnosis of mastocytosis: general histopathological aspects, morphological criteria, and immunohistochemical findings. *Leuk Res*. 2001;25(7):543-551.
- Metcalfe DD. Classification and diagnosis of mastocytosis: current status. *J Invest Dermatol*. 1991;96(3):2S-4S.
- Valent P. Biology, classification and treatment of human mastocytosis. *Wien Klin Wochenschr*. 1996;108(13):385-397.
- Valent P, Horny HP, Escribano L, et al. Diagnostic criteria and classification of mastocytosis: a consensus proposal. *Leuk Res*. 2001;25(7):603-625.
- Valent P, Horny H-P, Li CY, et al. Mastocytosis (mast cell disease). In: Jaffe ES, Harris NL, Stein H, Vardiman JW, eds. World Health Organization (WHO) Classification of Tumours. Pathology & Genetics. Tumours of Haematopoietic and Lymphoid Tissues. France: IARC Press Lyon; 2001:291-302.
- Horny HP, Akin C, Metcalfe DD, et al. Mastocytosis (mast cell disease). In: Swerdlow SH, Campo E, Harris NL, et al, eds. World Health Organization (WHO) Classification of Tumours. Pathology & Genetics. Tumours of Haematopoietic and Lymphoid Tissues. Lyon, France: IARC Press; 2008:54-63.
- Valent P, Akin C, Escribano L, et al. Standards and standardization in mastocytosis: consensus statements on diagnostics, treatment recommendations and response criteria. *Eur J Clin Invest*. 2007;37(6):435-453.
- Nettleship E, Tay W. Rare forms of urticaria. *Br Med J*. 1869;2:323-324.
- Ellis JM. Urticaria pigmentosa; a report of a case with autopsy. *Arch Pathol (Chic)*. 1949;48(5):426-435.
- Caplan RM. The natural course of urticaria pigmentosa. Analysis and follow-up of 112 cases. *Arch Dermatol*. 1963;87:146-157.
- Escribano L, Akin C, Castells M, Orfao A, Metcalfe DD. Mastocytosis: current concepts in diagnosis and treatment. *Ann Hematol*. 2002;81(12):677-690.
- Arock M, Valent P. Pathogenesis, classification and treatment of mastocytosis: state of the art in 2010 and future perspectives. *Expert Rev Hematol*. 2010;3(4):497-516.
- Theoharides TC, Valent P, Akin C. Mast cells, mastocytosis, and related disorders. *N Engl J Med*. 2015;373(2):163-172.
- Nagata H, Worobec AS, Oh CK, et al. Identification of a point mutation in the catalytic domain of the protooncogene c-kit in peripheral blood mononuclear cells of patients who have mastocytosis with an associated hematologic disorder. *Proc Natl Acad Sci USA*. 1995;92(23):10560-10564.
- Longley BJ, Tyrrell L, Lu SZ, et al. Somatic c-KIT activating mutation in urticaria pigmentosa and aggressive mastocytosis: establishment of clonality in a human mast cell neoplasm. *Nat Genet*. 1996;12(3):312-314.
- Fritzsche-Polanz R, Jordan JH, Feix A, et al. Mutation analysis of C-KIT in patients with myelodysplastic syndromes without mastocytosis and cases of systemic mastocytosis. *Br J Haematol*. 2001;113(2):357-364.
- Horny HP, Sillaber C, Menke D, et al. Diagnostic value of immunostaining for tryptase in patients with mastocytosis. *Am J Surg Pathol*. 1998;22(9):1132-1140.

22. Escribano L, Orfao A, Díaz-Agustín B, et al. Indolent systemic mast cell disease in adults: immunophenotypic characterization of bone marrow mast cells and its diagnostic implications. *Blood*. 1998;91(8):2731-2736.
23. Schwartz LB, Irani AM. Serum tryptase and the laboratory diagnosis of systemic mastocytosis. *Hematol Oncol Clin North Am*. 2000;14(3):641-657.
24. Sperr WR, Escribano L, Jordan JH, et al. Morphologic properties of neoplastic mast cells: delineation of stages of maturation and implication for cytological grading of mastocytosis. *Leuk Res*. 2001;25(7):529-536.
25. Valent P, Escribano L, Parwaresch RM, et al. Recent advances in mastocytosis research. Summary of the Vienna Mastocytosis Meeting 1998. *Int Arch Allergy Immunol*. 1999;120(1):1-7.
26. Arber DA, Orazi A, Hasserjian R, et al. The 2016 revision to the World Health Organization classification of myeloid neoplasms and acute leukemia. *Blood*. 2016;127(20):2391-2405.
27. Horny HP, Akin C, Arber D, et al. Mastocytosis. In: Swerdlow SH, Campo E, Harris NL, et al, eds. World Health Organization (WHO) Classification of Tumours. Pathology & Genetics. Tumours of Haematopoietic and Lymphoid Tissues. Lyon, France: IARC Press; 2016.
28. Hartmann K, Escribano L, Grattan C, et al. Cutaneous manifestations in patients with mastocytosis: consensus report of the European Competence Network on Mastocytosis; the American Academy of Allergy, Asthma & Immunology; and the European Academy of Allergology and Clinical Immunology. *J Allergy Clin Immunol*. 2016;137(1):35-45.
29. Valent P, Sotlar K, Sperr WR, et al. Refined diagnostic criteria and classification of mast cell leukemia (MCL) and myelomastocytic leukemia (MML): a consensus proposal. *Ann Oncol*. 2014;25(9):1691-1700.
30. Lim KH, Tefferi A, Lasho TL, et al. Systemic mastocytosis in 342 consecutive adults: survival studies and prognostic factors. *Blood*. 2009;113(23):5727-5736.
31. Escribano L, Alvarez-Twose I, Sánchez-Muñoz L, et al. Prognosis in adult indolent systemic mastocytosis: a long-term study of the Spanish Network on Mastocytosis in a series of 145 patients. *J Allergy Clin Immunol*. 2009;124(3):514-521.
32. Pardanani A, Lim KH, Lasho TL, et al. Prognostically relevant breakdown of 123 patients with systemic mastocytosis associated with other myeloid malignancies. *Blood*. 2009;114(18):3769-3772.
33. Pardanani A, Lim KH, Lasho TL, et al. WHO subvariants of indolent mastocytosis: clinical details and prognostic evaluation in 159 consecutive adults. *Blood*. 2010;115(1):150-151.
34. Travis WD, Li CY, Hoagland HC, Travis LB, Banks PM. Mast cell leukemia: report of a case and review of the literature. *Mayo Clin Proc*. 1986;61(12):957-966.
35. Valent P, Sotlar K, Sperr WR, Reiter A, Arock M, Horny HP. Chronic mast cell leukemia: a novel leukemia-variant with distinct morphological and clinical features. *Leuk Res*. 2015;39(1):1-5.
36. Arock M, Sotlar K, Akin C, et al. KIT mutation analysis in mast cell neoplasms: recommendations of the European Competence Network on Mastocytosis. *Leukemia*. 2015;29(6):1223-1232.
37. Mayerhofer M, Gleixner KV, Hoelbl A, et al. Unique effects of KIT D816V in BaF3 cells: induction of cluster formation, histamine synthesis, and early mast cell differentiation antigens. *J Immunol*. 2008;180(8):5466-5476.
38. Zappulla JP, Dubreuil P, Desbois S, et al. Mastocytosis in mice expressing human Kit receptor with the activating Asp816Val mutation. *J Exp Med*. 2005;202(12):1635-1641.
39. Ma Y, Zeng S, Metcalfe DD, et al. The c-KIT mutation causing human mastocytosis is resistant to STI571 and other KIT kinase inhibitors; kinases with enzymatic site mutations show different inhibitor sensitivity profiles than wild-type kinases and those with regulatory-type mutations. *Blood*. 2002;99(5):1741-1744.
40. Akin C, Brockow K, D'Ambrosio C, et al. Effects of tyrosine kinase inhibitor STI571 on human mast cells bearing wild-type or mutated c-kit. *Exp Hematol*. 2003;31(8):686-692.
41. Akin C, Fumo G, Yavuz AS, Lipsky PE, Neckers L, Metcalfe DD. A novel form of mastocytosis associated with a transmembrane c-kit mutation and response to imatinib. *Blood*. 2004;103(8):3222-3225.
42. Bodemer C, Hermine O, Palmérini F, et al. Pediatric mastocytosis is a clonal disease associated with D816V and other activating c-KIT mutations. *J Invest Dermatol*. 2010;130(3):804-815.
43. Zhang LY, Smith ML, Schultheis B, et al. A novel K509I mutation of KIT identified in familial mastocytosis-in vitro and in vivo responsiveness to imatinib therapy. *Leuk Res*. 2006;30(4):373-378.
44. Alvarez-Twose I, González P, Morgado JM, et al. Complete response after imatinib mesylate therapy in a patient with well-differentiated systemic mastocytosis. *J Clin Oncol*. 2012;30(12):e126-e129.
45. de Melo Campos P, Machado-Neto JA, Scopim-Ribeiro R, et al. Familial systemic mastocytosis with germline KIT K509I mutation is sensitive to treatment with imatinib, dasatinib and PKC412. *Leuk Res*. 2014;38(10):1245-1251.
46. Harir N, Boudot C, Friedbichler K, et al. Oncogenic Kit controls neoplastic mast cell growth through a Stat5/Pl3-kinase signaling cascade. *Blood*. 2008;112(6):2463-2473.
47. Blatt K, Herrmann H, Mirkina I, et al. The Pl3-kinase/mTOR-targeting drug NVP-BE2235 inhibits growth and IgE-dependent activation of human mast cells and basophils. *PLoS One*. 2012;7(1):e29925.
48. Gabillot-Carré M, Lepelletier Y, Humbert M, et al. Rapamycin inhibits growth and survival of D816V-mutated c-kit mast cells. *Blood*. 2006;108(3):1065-1072.
49. Baumgartner C, Cerny-Reiterer S, Sonneck K, et al. Expression of activated STAT5 in neoplastic mast cells in systemic mastocytosis: subcellular distribution and role of the transforming oncoprotein KIT D816V. *Am J Pathol*. 2009;175(6):2416-2429.
50. Voisset E, Lopez S, Dubreuil P, De Sepulveda P. The tyrosine kinase FES is an essential effector of KITD816V proliferation signal. *Blood*. 2007;110(7):2593-2599.
51. Peter B, Winter GE, Blatt K, et al. Target interaction profiling of midostaurin and its metabolites in neoplastic mast cells predicts distinct effects on activation and growth. *Leukemia*. 2016;30(2):464-472.
52. Parikh SA, Kantarjian HM, Richie MA, Cortes JE, Verstovsek S. Experience with everolimus (RAD001), an oral mammalian target of rapamycin inhibitor, in patients with systemic mastocytosis. *Leuk Lymphoma*. 2010;51(2):269-274.
53. Traina F, Visconte V, Jankowska AM, et al. Single nucleotide polymorphism array lesions, TET2, DNMT3A, ASXL1 and CBL mutations are present in systemic mastocytosis. *PLoS One*. 2012;7(8):e43090.
54. Wilson TM, Maric I, Simakova O, et al. Clonal analysis of NRAS activating mutations in KIT-D816V systemic mastocytosis. *Haematologica*. 2011;96(3):459-463.
55. Schwaab J, Schnittger S, Sotlar K, et al. Comprehensive mutational profiling in advanced systemic mastocytosis. *Blood*. 2013;122(14):2460-2466.
56. Damaj G, Joris M, Chandesris O, et al. ASXL1 but not TET2 mutations adversely impact overall survival of patients suffering systemic mastocytosis with associated clonal hematologic non-mast-cell diseases. *PLoS One*. 2014;9(1):e85362.
57. Gleixner KV, Mayerhofer M, Cerny-Reiterer S, et al. KIT-D816V-independent oncogenic signaling in neoplastic cells in systemic mastocytosis: role of Lyn and Btk activation and disruption by dasatinib and bosutinib. *Blood*. 2011;118(7):1885-1898.
58. Sotlar K, Bache A, Stellmacher F, Bültmann B, Valent P, Horny HP. Systemic mastocytosis associated with chronic idiopathic myelofibrosis: a distinct subtype of systemic mastocytosis associated with a clonal hematological non-mast cell lineage disorder carrying the activating point mutations KITD816V and JAK2V617F. *J Mol Diagn*. 2008;10(1):58-66.
59. Broesby-Olsen S, Kristensen TK, Møller MB, Bindsløv-Jensen C, Vestergaard H; Mastocytosis Centre, Odense University Hospital (MastOUH). Adult-onset systemic mastocytosis in monozygotic twins with KIT D816V and JAK2 V617F mutations. *J Allergy Clin Immunol*. 2012;130(3):806-808.
60. Ghanim V, Herrmann H, Heller G, et al. 5-azacytidine and decitabine exert proapoptotic effects on neoplastic mast cells: role of FAS-demethylation and FAS re-expression, and synergism with FAS-ligand. *Blood*. 2012;119(18):4242-4252.
61. Wedeh G, Cerny-Reiterer S, Eisenwort G, et al. Identification of bromodomain-containing protein-4 as a novel marker and epigenetic target in mast cell leukemia. *Leukemia*. 2015;29(11):2230-2237.
62. Aichberger KJ, Mayerhofer M, Gleixner KV, et al. Identification of MCL1 as a novel target in neoplastic mast cells in systemic mastocytosis: inhibition of mast cell survival by MCL1 antisense oligonucleotides and synergism with PKC412. *Blood*. 2007;109(7):3031-3041.
63. Fumo G, Akin C, Metcalfe DD, Neckers L. 17-Allylamino-17-demethoxygeldanamycin (17-AAG) is effective in down-regulating mutated, constitutively activated KIT protein in human mast cells. *Blood*. 2004;103(3):1078-1084.
64. Kondo R, Gleixner KV, Mayerhofer M, et al. Identification of heat shock protein 32 (Hsp32) as a novel survival factor and therapeutic target in neoplastic mast cells. *Blood*. 2007;110(2):661-669.
65. Santos DD, Hatjiharissi E, Tournilhac O, et al. CD52 is expressed on human mast cells and is a potential therapeutic target in Waldenström's macroglobulinemia and mast cell disorders. *Clin Lymphoma Myeloma*. 2006;6(6):478-483.
66. Krauth MT, Böhm A, Agis H, et al. Effects of the CD33-targeted drug gemtuzumab ozogamicin (Mylotarg) on growth and mediator secretion in human mast cells and blood basophils. *Exp Hematol*. 2007;35(1):108-116.
67. Sotlar K, Cerny-Reiterer S, Petat-Dutter K, et al. Aberrant expression of CD30 in neoplastic mast cells in high-grade mastocytosis. *Mod Pathol*. 2011;24(4):585-595.
68. Morgado JM, Perbellini O, Johnson RC, et al. CD30 expression by bone marrow mast cells from different diagnostic variants of systemic

- mastocytosis. *Histopathology*. 2013;63(6):780-787.
69. Hoermann G, Blatt K, Greiner G, et al. CD52 is a molecular target in advanced systemic mastocytosis. *FASEB J*. 2014;28(8):3540-3551.
  70. Blatt K, Cerny-Reiterer S, Schwaab J, et al. Identification of the Ki-1 antigen (CD30) as a novel therapeutic target in systemic mastocytosis. *Blood*. 2015;126(26):2832-2841.
  71. Pardanani A, Lasho T, Chen D, et al. Aberrant expression of CD123 (interleukin-3 receptor- $\alpha$ ) on neoplastic mast cells. *Leukemia*. 2015;29(7):1605-1608.
  72. Jeong DK, Fauman K, Ross C, Akin C, Mody R. Successful treatment of systemic mastocytosis associated with AML-M2, t(8;21) in a child using MRC-based AML chemotherapy along with gemtuzumab. *J Allergy Clin Immunol*. 2007;119(S1):207.
  73. Alvarez-Twose I, Martínez-Barranco P, Gotlib J, et al. Complete response to gemtuzumab ozogamicin in a patient with refractory mast cell leukemia. *Leukemia*. 2016;30(8):1753-1756.
  74. Rabenhorst A, Leja S, Schwaab J, et al. Expression of programmed cell death ligand-1 in mastocytosis correlates with disease severity. *J Allergy Clin Immunol*. 2016;137(1):314-318.
  75. Valent P. Targeting of leukemia-initiating cells to develop curative drug therapies: straightforward but nontrivial concept. *Curr Cancer Drug Targets*. 2011;11(1):56-71.
  76. Pelosi E, Castelli G, Testa U. Targeting LSCs through membrane antigens selectively or preferentially expressed on these cells. *Blood Cells Mol Dis*. 2015;55(4):336-346.
  77. Eisenwort G, Peter B, Blatt K, et al. Identification of a neoplastic stem cell in human mast cell leukemia. *Blood*. 2014;124(21):817.
  78. Kluijn-Nelemans HC, Jansen JH, Breukelman H, et al. Response to interferon alfa-2b in a patient with systemic mastocytosis. *N Engl J Med*. 1992;326(9):619-623.
  79. Casassus P, Caillat-Vigneron N, Martin A, et al. Treatment of adult systemic mastocytosis with interferon-alpha: results of a multicentre phase II trial on 20 patients. *Br J Haematol*. 2002;119(4):1090-1097.
  80. Lim KH, Pardanani A, Butterfield JH, Li CY, Tefferi A. Cytoreductive therapy in 108 adults with systemic mastocytosis: Outcome analysis and response prediction during treatment with interferon-alpha, hydroxyurea, imatinib mesylate or 2-chlorodeoxyadenosine. *Am J Hematol*. 2009;84(12):790-794.
  81. Kluijn-Nelemans HC, Oldhoff JM, Van Doormaal JJ, et al. Cladribine therapy for systemic mastocytosis. *Blood*. 2003;102(13):4270-4276.
  82. Barete S, Lortholary O, Damaj G, et al. Long-term efficacy and safety of cladribine (2-CdA) in adult patients with mastocytosis. *Blood*. 2015;126(8):1009-1016, quiz 1050.
  83. Ustun C, Reiter A, Scott BL, et al. Hematopoietic stem-cell transplantation for advanced systemic mastocytosis. *J Clin Oncol*. 2014;32(29):3264-3274.
  84. Ustun C, Gotlib J, Popat U, et al. Consensus opinion on allogeneic hematopoietic cell transplantation in advanced systemic mastocytosis. *Biol Blood Marrow Transplant*. 2016;22(8):1348-1356.
  85. Fabbro D, Ruetz S, Bodis S, et al. PKC412—a protein kinase inhibitor with a broad therapeutic potential. *Anticancer Drug Des*. 2000;15(1):17-28.
  86. Ustun C, DeRemer DL, Akin C. Tyrosine kinase inhibitors in the treatment of systemic mastocytosis. *Leuk Res*. 2011;35(9):1143-1152.
  87. Gowney JD, Clark JJ, Adelsperger J, et al. Activation mutations of human c-KIT resistant to imatinib mesylate are sensitive to the tyrosine kinase inhibitor PKC412. *Blood*. 2005;106(2):721-724.
  88. Gleixner KV, Mayerhofer M, Aichberger KJ, et al. PKC412 inhibits in vitro growth of neoplastic human mast cells expressing the D816V-mutated variant of KIT: comparison with AMN107, imatinib, and cladribine (2CdA) and evaluation of cooperative drug effects. *Blood*. 2006;107(2):752-759.
  89. Gotlib J, Berubé C, Gowney JD, et al. Activity of the tyrosine kinase inhibitor PKC412 in a patient with mast cell leukemia with the D816V KIT mutation. *Blood*. 2005;106(8):2865-2870.
  90. Krauth MT, Mirkina I, Herrmann H, Baumgartner C, Kneidinger M, Valent P. Midostaurin (PKC412) inhibits immunoglobulin E-dependent activation and mediator release in human blood basophils and mast cells. *Clin Exp Allergy*. 2009;39(11):1711-1720.
  91. Gotlib J, Kluijn-Nelemans HC, George TI, et al. Efficacy and safety of midostaurin in advanced systemic mastocytosis. *N Engl J Med*. 2016;374(26):2530-2541.
  92. Chandesris MO, Damaj G, Canioni D, et al; CEREMAST Study Group. Midostaurin in advanced systemic mastocytosis. *N Engl J Med*. 2016;374(26):2605-2607.
  93. Gotlib J, Kluijn-Nelemans HC, George TI, et al. Durable responses and improved quality of life with midostaurin (PKC412) in advanced systemic mastocytosis (SM): updated stage 1 results of the global D2201 trial. *Blood*. 2013;122:106.
  94. Vega-Ruiz A, Cortes JE, Sever M, et al. Phase II study of imatinib mesylate as therapy for patients with systemic mastocytosis. *Leuk Res*. 2009;33(11):1481-1484.
  95. Paul C, Sans B, Suarez F, et al. Masitinib for the treatment of systemic and cutaneous mastocytosis with handicap: a phase 2a study. *Am J Hematol*. 2010;85(12):921-925.
  96. Hochhaus A, Baccarani M, Giles FJ, et al. Nilotinib in patients with systemic mastocytosis: analysis of the phase 2, open-label, single-arm nilotinib registration study. *J Cancer Res Clin Oncol*. 2015;141(11):2047-2060.
  97. Alvarez-Twose I, Matito A, Morgado JM, et al. Imatinib in systemic mastocytosis: a phase IV clinical trial in patients lacking exon 17 KIT mutations and review of the literature [published online ahead of print 19 July 2016]. *Oncotarget*. doi:10.18632/oncotarget.10711.
  98. Pardanani A. How I treat patients with indolent and smoldering mastocytosis (rare conditions but difficult to manage). *Blood*. 2013;121(16):3085-3094.
  99. Arock M, Akin C, Hermine O, Valent P. Current treatment options in patients with mastocytosis: status in 2015 and future perspectives. *Eur J Haematol*. 2015;94(6):474-490.
  100. Valent P, Sperr WR, Akin C. How I treat patients with advanced systemic mastocytosis. *Blood*. 2010;116(26):5812-5817.
  101. Wimazal F, Geissler P, Shnawa P, Sperr WR, Valent P. Severe life-threatening or disabling anaphylaxis in patients with systemic mastocytosis: a single-center experience. *Int Arch Allergy Immunol*. 2012;157(4):399-405.
  102. Valent P, Akin C, Sperr WR, et al. Aggressive systemic mastocytosis and related mast cell disorders: current treatment options and proposed response criteria. *Leuk Res*. 2003;27(7):635-641.
  103. Gotlib J, Pardanani A, Akin C, et al. International Working Group-Myeloproliferative Neoplasms Research and Treatment (IWG-MRT) & European Competence Network on Mastocytosis (ECNM) consensus response criteria in advanced systemic mastocytosis. *Blood*. 2013;121(13):2393-2401.





2017 129: 1420-1427

doi:10.1182/blood-2016-09-731893 originally published  
online December 28, 2016

## **Mastocytosis: 2016 updated WHO classification and novel emerging treatment concepts**

Peter Valent, Cem Akin and Dean D. Metcalfe

---

Updated information and services can be found at:

<http://www.bloodjournal.org/content/129/11/1420.full.html>

Articles on similar topics can be found in the following Blood collections

[Clinical Trials and Observations](#) (5007 articles)

[Free Research Articles](#) (5498 articles)

[Myeloid Neoplasia](#) (1990 articles)

[Phagocytes, Granulocytes, and Myelopoiesis](#) (710 articles)

[Review Articles](#) (844 articles)

---

Information about reproducing this article in parts or in its entirety may be found online at:

[http://www.bloodjournal.org/site/misc/rights.xhtml#repub\\_requests](http://www.bloodjournal.org/site/misc/rights.xhtml#repub_requests)

Information about ordering reprints may be found online at:

<http://www.bloodjournal.org/site/misc/rights.xhtml#reprints>

Information about subscriptions and ASH membership may be found online at:

<http://www.bloodjournal.org/site/subscriptions/index.xhtml>